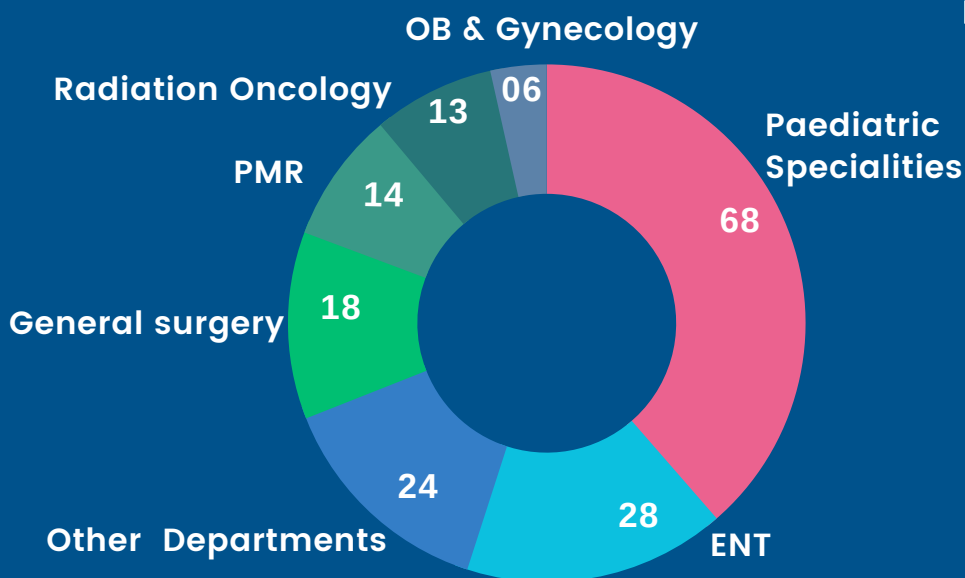


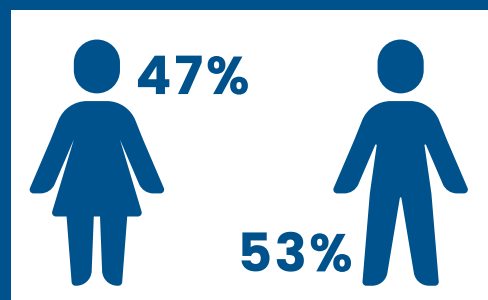
Person-to-Person

Treating Departments



171 Patients supported

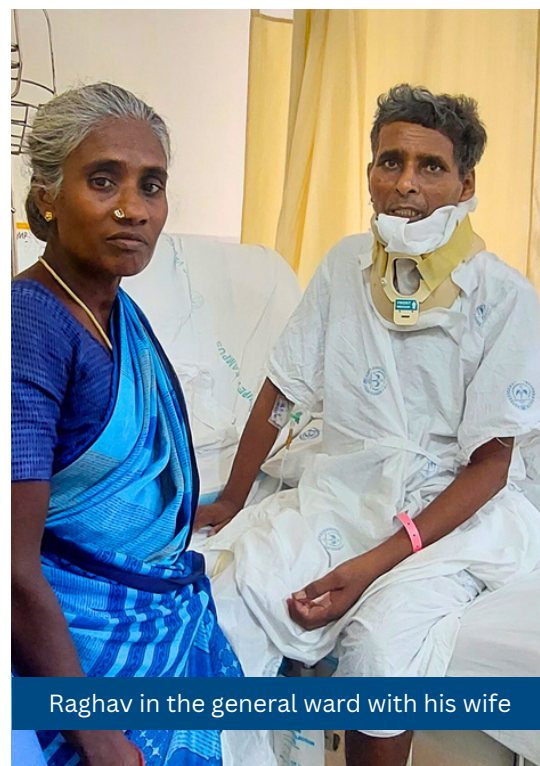By PTP In October 2023



51-year-old Ragav and his family live in a small village near Vellore. The family own a few cows and earn their living from selling milk every day. Ragav's only son works in a shoe factory. Last year, Ragav felt his legs getting stiff and the tightness worsened progressively. He struggled to walk, to bend down or squat. Over time, the stiffness spread to his hands. He found it hard to hold anything or even eat with his fingers. Eventually, he could not move and was confined to his bed for six months. Raghav's son had to quit his job to take care of him. Treatment from a nearby hospital did not help him get better.

His family brought him to CMC Vellore where he was seen by specialists in various departments for diabetes, kidney disease. He was admitted to CHAD hospital to bring his sugars and urinary infection under control. A month later, he was well enough to be admitted under the Department of

Neurosurgery for treatment of Cervical Spondylotic Myelopathy, an age-related degenerative condition. The compression of his spinal cord resulted in his stiff limbs and walking problems. Ragav had a decompression surgery to help him regain his mobility. He recovered well after surgery and is able to sit up and walk slowly. He was advised physiotherapy and continues to visit CMC for regular check-ups.



Raghav in the general ward with his wife

Thank you for your thoughtful giving!

**patient details shared with consent & name changed to protect their privacy*



Thank you FOV UK!
Your contribution of £1716 supported 18 patients
at CMC Vellore in October 2023

S.No	Unique Ref ID	PTP Amount in ₹	Age	Gender	Outcome	Department	Diagnosis
1	23100463198	10000	61	F	Significantly Improved	Ophthalmology	Small Incision Cataract Surgery+Trabeculectomy
2	23092362539	10000	33	F	Fully recovered	General Surgery	Laparoscopic Cholecystectomy
3	23092362561	10000	72	M	Significantly Improved	General Surgery	Medical Management with antibiotics, analgesia, CT guided pihthead insertion,
4	23100263056	10000	11	F	Significantly Improved	Paediatrics	Medical Management with Antibiotics
5	23100163002	10000	4	M	Significantly Improved	Paediatrics	Medical Management with Antibiotics and antifungals
6	23100163022	10000	48	M	Significantly Improved	Dermatology	Medical Management with Steroids, antibiotics, anti virals

S.No	Unique Ref ID	PTP Amount in ₹	Age	Gender	Outcome	Department	Diagnosis
7	23100163016	10000	1	F	Significantly Improved	Paediatric	Medical Management with antibiotics, high flow oxygen
8	23100163023	10000	19	F	Significantly Improved	Pulmonary Medicine	Chest Tube (Intercostal Drainage) ICD Insertion ATT
9	23100163027	10000	1	M	Significant residual morbidity	Paediatric Neurology	Calcium edetate chelation
10	23100263088	10000	36	M	Significantly Improved	Physical Medicine & Rehab	Management of spasticity, improving communication
11	23100263092	10000	3	M	Significantly Improved	Paediatrics	Medical Management with antibiotics and Oxygen
12	23100363147	10000	17	M	Significantly Improved	E.N.T	Right Full Functional endoscopy sinus surgery. with Left Concha Bullosa Resection
13	23100363152	10000	25	M	Fully recovered	General Medicine	Supportive management with IV Antibiotics.
14	23100163026	10000	35	F	Significantly Improved	Dermatology	Medical Management with steroids and immunosuppression.
15	23100463176	10000	40	M	Fully recovered	E.N.T	Right tympanoplasty
16	23100363109	10000	38	M	Significant residual morbidity	Physical Medicine & Rehab	Management of UTI, neurogenic bowel, bladder, ambulation training,
17	23100463185	10000	17	M	Fully recovered	E.N.T	Bilateral Revision Endoscopic Dacrocystorhinostomy Under GA
18	23100363127	10000	47	M	Significant residual morbidity	Physical Medicine & Rehab	Ambulation training, tracheostomy decannulation, management of tracheocutaneous fistula, Swallowing therapy and physiotherapy for improved independence in activities of daily living.
		1,80,000					18